



# Zimmer® MAYO® Conservative Hip Prosthesis

Surgical Technique



Multi Point Fixation with Minimal Bone Loss



## MAYO\* Conservative Hip Prosthesis Surgical Technique

Developed in conjunction with

### **Bernard F. Morrey, M.D.**

Professor and Chairman  
Department of Orthopaedic Surgery  
Mayo Clinic  
Rochester, MN

## Table of Contents

<b>Indications</b>	<b>2</b>
<b>Instrumentation</b>	<b>2</b>
<b>Preoperative Planning</b>	<b>2</b>
Determination of Leg Length	2
Determination of Abductor Muscle Tension and Femoral Offset	3
Component Size Selection/Templating	3
<b>Surgical Technique</b>	<b>6</b>
Surgical Exposure	6
Femoral Neck Osteotomy	6
Medullary Canal Identification	6
Femoral Preparation	7
Stability and Trial Reduction	8
Component Insertion	10
Anteversión	11
Attachment of the Femoral Head	11
<b>Technical Notes</b>	<b>11</b>
Rasping the Femur	11
Implant Insertion	11
<b>Postoperative Rehabilitation</b>	<b>11</b>

\* Mayo is a registered trademark of the Mayo Foundation

## Indications

The indications for the *MAYO* prosthesis are, in general, the same as those for any primary hip replacement: relieve pain and restore function. The conservative features of minimal bone resection and favorable proximal femoral remodeling make the *MAYO* prosthesis ideal for primary total hip replacement. The *MAYO* hip is indicated for cementless use in skeletally mature individuals undergoing primary surgery for total hip replacement. Diagnostic indications include severe hip pain and disabilities due to rheumatoid arthritis, osteoarthritis, traumatic arthritis, polyarthritis, slipped capital femoral epiphysis, fused hip, fracture of the pelvis, and diastrophic variant.

## Instrumentation

The instrumentation is uncomplicated and is compatible with current Zimmer hip replacement systems.

The rasp handle is interchangeable with other Zimmer systems. The modular sizing obtained with the 12/14 Morse-type taper neck design is identical to that of other Zimmer modular 12/14 head and neck components. Thus, the sizes, lengths, and modular 12/14 heads available for other Zimmer implants are interchangeable with this design.

## Preoperative Planning

Effective preoperative planning allows the surgeon to predict the impact of different interventions in order to perform the joint restoration in the most accurate and safest manner. Optimal femoral stem fit, the level of the femoral neck cut, the prosthetic neck length, and the femoral component offset can be evaluated through preoperative radiographic analysis. Preoperative planning also allows the surgeon to have the appropriate implants available at surgery.

The objectives of preoperative planning include:

1. Determination of leg length,
2. Establishment of appropriate abductor muscle tension and femoral offset, and
3. Determination of the anticipated component sizes.

The overall objective of preoperative planning is to enable the surgeon to gather anatomic parameters which will allow accurate intraoperative placement of the femoral implant.

## Determination of Leg Length

Determining the preoperative leg length is essential for restoration of the appropriate leg length during surgery. For most patients, leg lengths are not equal. If leg lengths are equal in both the recumbent and standing positions, the leg length determination is simplified. If there are concerns regarding other lower extremity abnormalities, such as equinus of the foot or significant flexion or varus/valgus deformities of the knee, perform further radiographic evaluation to aid in the determination of preoperative leg length status.

An A/P pelvic radiograph often gives enough documentation of leg length inequality to proceed with surgery. If more information is needed, a scanogram or CT evaluation of leg length may be helpful. From the clinical and radiographic information on leg lengths, determine the appropriate correction, if any, to be achieved during surgery.

If the limb is to be significantly shortened, osteotomy and advancement of the greater trochanter may be necessary. If the limb is shortened without osteotomy and advancement of the greater trochanter, the abductors will be lax postoperatively, and the risk of dislocation will be high. Also, gait will be compromised by the laxity of the abductors.

If leg length is to be maintained or increased, it is usually possible to perform the operation successfully without osteotomy of the greater trochanter. However, if there is some major anatomic abnormality, osteotomy of the greater trochanter may be helpful.

### Determination of Abductor Muscle Tension and Femoral Offset

Once the requirements for establishing the desired postoperative leg length have been decided, the next step is to consider the requirement for abductor muscle tension. When the patient has a very large offset between the center of rotation of the femoral head and the line that bisects the medullary canal, the insertion of a femoral component with a lesser offset will, in effect, medialize the femoral shaft. To the extent that this occurs, laxity in the abductors will result.

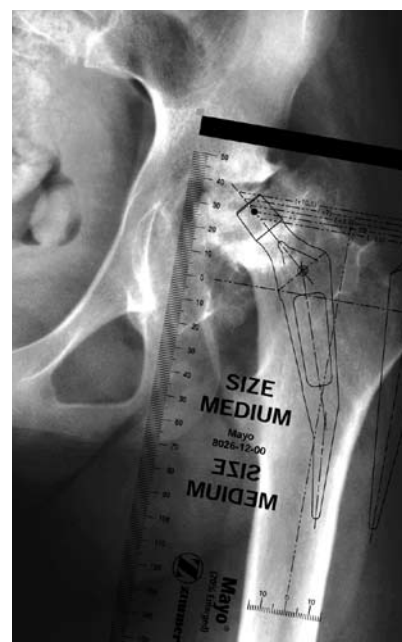
Although rare, it may not be possible to restore offset in patients with an unusually large preoperative offset or with a severe varus deformity. In such cases, the tension in the abductors can be increased by lengthening the limb, a method that is especially useful when the involved hip is short. If this option is not advisable and if the disparity is great between the preoperative offset and the offset achieved at surgery by using the longest head-neck piece possible, some surgeons may choose to osteotomize and advance the greater trochanter to eliminate the slack in the abductor muscles. Technical variations in the placement of the acetabular components can also reduce the differences in offset.

### Component Size Selection/ Templating

Preoperative planning for insertion of a cementless femoral component requires at least two views of the involved femur: an anterior/posterior (A/P) view of the pelvis centered at the pubic symphysis, and a frog leg lateral view on an 11x17-inch cassette (Fig. 1). Both views should show at least 8 inches of the proximal femur. In addition, it may be helpful to obtain an A/P view of the involved side with the femur internally rotated. This compensates for naturally occurring femoral anteversion and provides a more accurate representation of the true medial to lateral dimension of the metaphysis.

When templating, magnification of the femur will vary depending on the distance from the X-ray source to the film and the distance from the patient to the film. The MAYO Conservative Hip System templates use standard 15 and 20 percent magnification, which is near the average magnification on most clinical X-rays.

Large patients and obese patients may have magnification greater than 20 percent because their osseous structures are farther away from the surface of the film. Similarly, smaller patients may have magnification less than 20 percent. To better determine the magnification of any X-ray film, use a standardized marker at the level of the femur.



Note: It is not uncommon to have an appropriately sized device appear undersized on the A/P view.



Fig. 1

Preoperative planning is important in choosing the optimal acetabular component and in providing an estimation of the range of acetabular components that might ultimately be required.

The initial templating begins with the A/P roentgenogram. Superimpose the acetabular templates sequentially on the pelvic X-ray with the acetabular component in approximately 40 degrees of abduction. Range of motion and hip stability are optimized when the socket is placed in approximately 35 to 45 degrees of abduction. Assess several sizes to estimate which acetabular component will provide the best fit for maximum coverage. In most cases, select the largest component possible, being certain that the outside diameter isn't too large to seat completely in the acetabulum. (Refer to the Zimmer *Trilogy*<sup>®</sup> Acetabular System surgical technique for further details on acetabular reconstruction.) Consider the position and thickness of the acetabular component in estimating the optimum femoral neck length to be used. (To simplify this, the acetabular templates are on a separate acetate sheet from the femoral templates.) Mark the acetabular size and position, and the center of the head on the X-rays. This allows any femoral component to be matched with the desired acetabular component by placing the femoral template over the acetabular template. This will provide the best estimation of femoral component size and head-neck length necessary to achieve the correct leg length.

The *VerSys*<sup>®</sup> Hip System includes four head diameters for use with the *MAYO* Conservative Hip System. In most patients with average-sized acetabula, consider a femoral head with an intermediate diameter, such as 26mm or 28mm. The intermediate femoral heads allow the use of an acetabular component with an outside diameter small enough to seat completely in the bone while also allowing for a polyethylene liner of sufficient thickness. If a ceramic head is desired, that option is also available.

In special circumstances, such as the treatment of small patients and patients with small acetabular volume, it is preferable to use a 22mm diameter head to allow for adequate polyethylene thickness.

The specific objectives in templating the femoral component include:

1. determining the anticipated size of the implant to be inserted, and
2. determining the height of the implant in the femur and the location of the femoral neck osteotomy.

Now select the appropriate femoral template. The femoral templates show the neck length and offset for each of the head/neck combinations. Note that skirts are present on some heads.

To estimate the femoral implant size, assess both the distal stem size and the body size on the A/P radiograph, and then check the stem size on the lateral radiograph. Superimpose the template on the isthmus and estimate the appropriate size of the femoral stem. Assess the fit of the body in the metaphyseal area. The medial portion of the body of the component should fill the proximal metaphysis as fully as possible, compatible with the anatomic endosteal contours of that region. The optimal insertion on the A/P projection is alignment of the lateral margin of the implants with the lateral margin of the femoral cortex (Fig. 2).

Next, check the fit of the stem on the lateral X-ray. If the lateral X-ray reveals that the A/P dimension of the isthmus is greater than the medial-lateral (M/L) dimension shown on the A/P film, it may be advantageous to increase the size of the stem to better fill the isthmus.

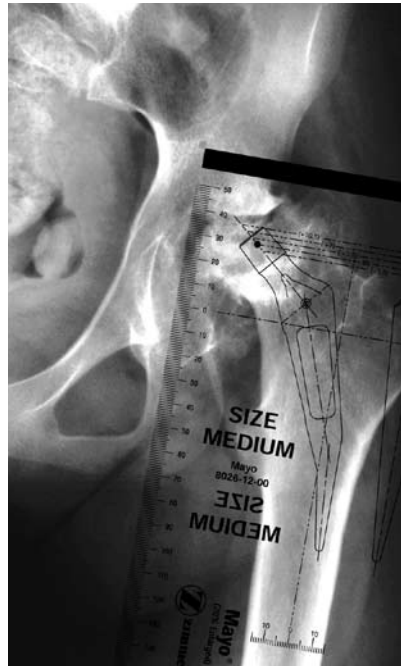


Fig. 2

Careful attention during this process helps the surgeon achieve the goal of implanting a stem that will provide maximum stability and contact with the host bone.

After establishing the proper size of the femoral component, determine the height of its position in the proximal femur and the amount of offset needed to provide adequate abductor muscle tension. Generally, if the leg length and offset are to remain unchanged, the center of the head of the prosthesis should be at the same level as the center of the femoral head of the patient's hip. This should also correspond to the center of rotation of the templated acetabulum. To lengthen the limb, raise the template proximally. To shorten the limb, shift the template distally.

Once the height has been determined, note the distance in millimeters from the underside of the collar to the top of the lesser trochanter by using the millimeter scale on the template. For example, one might decide from the templating that a 52mm OD socket, with a size medium prosthesis and a +3.5 x 28mm diameter femoral head, placed 15mm above the lesser trochanter, are the appropriate choices.

Proximal/distal adjustments in prosthesis position can reduce the need for a femoral head with a longer neck and skirt. (The skirted heads allow less range of motion than the non-skirted heads, which may increase the chance of dislocation.)

## Surgical Technique

### Step 1 - Surgical Exposure

In total hip arthroplasty, exposure can be achieved through a variety of approaches based on the surgeon's preference. The *MAYO* Conservative Hip Prosthesis can be implanted using the anterolateral, posterolateral, or straight lateral approaches. Because the neck is preserved, the transtrochanteric approach is typically not employed.

### Step 2 - Femoral Neck Osteotomy

The most important consideration regarding the femoral neck resection is to assure that optimum abductor mechanics are restored by the proper length of resection. Typically, the tip of the greater trochanter is aligned with the center of the femoral head to restore the normal mechanics of the hip abductor system (Fig. 3).

In most instances, proper resection of the femoral neck provides for the standard (0mm) length femoral neck implant. To accomplish this, align the hole on the cutting jig with the center of the femoral head. Perform this resection with a single cut that does not violate the lateral cortex of the femoral neck or the trochanter and is usually about 1.5-2cm proximal to the lesser trochanter (Fig. 3). The line of osteotomy is dictated by the template, and the orientation of the femoral neck cut assists in determining the desired orientation of the implant (Fig. 4).

Use the table below to choose the appropriate osteotomy guide which corresponds to the intended implant size.

Implant Size	Osteotomy Guide
S	Small
S+	Small
M	Medium
M+	Medium
L	Large
L+	Large
XL	X-Large

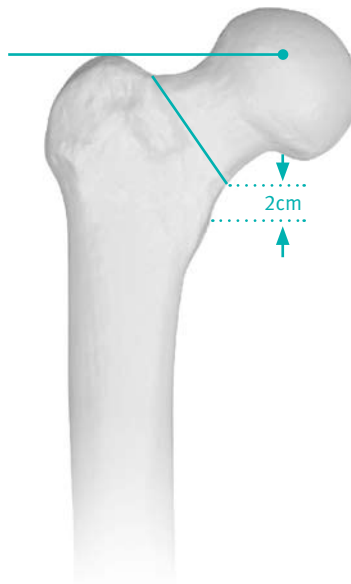


Fig. 3

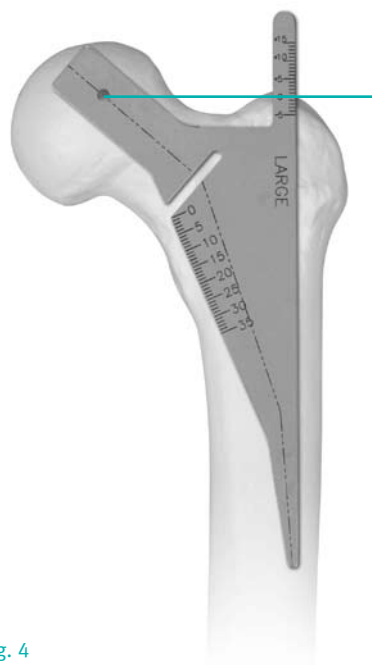

Fig. 4

### Step 3 - Medullary Canal Identification

The lateral neck of the femur is not violated.

The medullary canal is identified first by a curved awl with the same curve as the implant. This identifies the medullary canal, and a rotatory motion clears the proximal femur of cancellous bone, making initial insertion of the rasp more easily accomplished (Fig. 5).

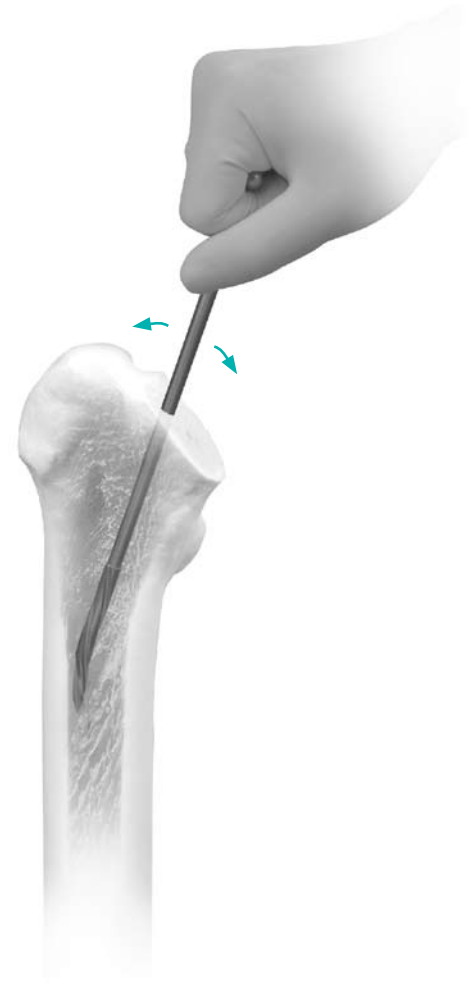


Fig. 5

Note: Care should be taken to not use osteotomy guides and cone provisionals from the old *MAYO* System which has the six degree taper.

#### Step 4 - Femoral Preparation

Use the smallest size femoral rasp first. The tail of the rasp should contact, and be parallel to, the lateral cortex of the femur. Start with the rasp inserted in a slight varus orientation (Fig. 6). As the rasp is driven down the canal, it assumes a more valgus position. Evaluate proper orientation by observing that the line defining the proximal row of teeth on the rasp is parallel to the line of neck resection (Fig. 7).

Drive the small rasp down the canal so that the top row of teeth is at the line of resection. If this rasp can be further impacted by 2mm to 3mm, use the next size rasp in a similar fashion. The rasp is designed to remove bone in the A/P plane in such a way as to allow point contact at the medial neck several millimeters distal to the resection and at the lateral aspect of the femoral shaft just below the trochanter.

In the lateral plane, point contact is obtained: 1) posteriorly along the femoral neck, 2) anteriorly at the junction between the neck and the anterior shaft, and 3) posteriorly with the stem resting against the cortex just distal to the lesser trochanter.

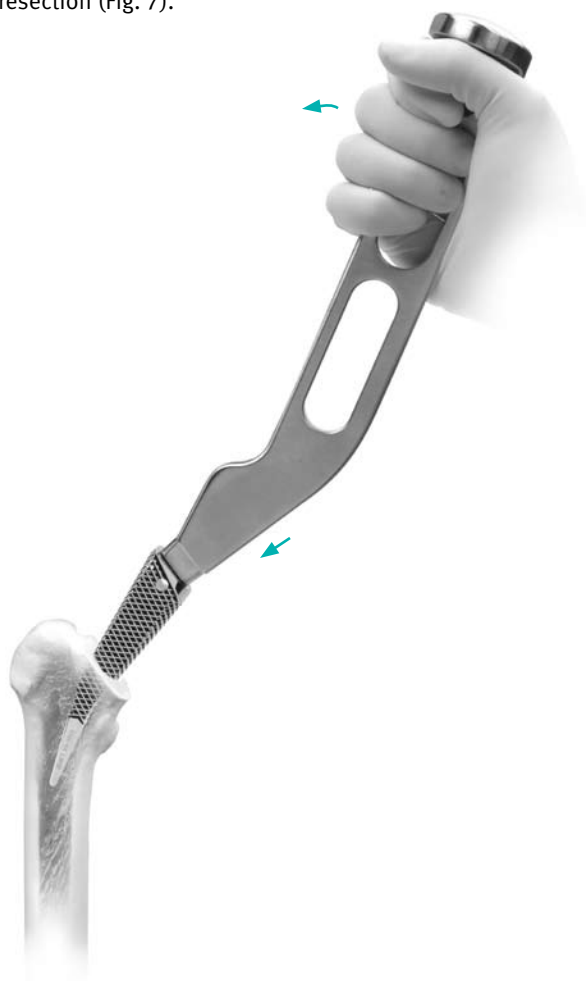


Fig. 6

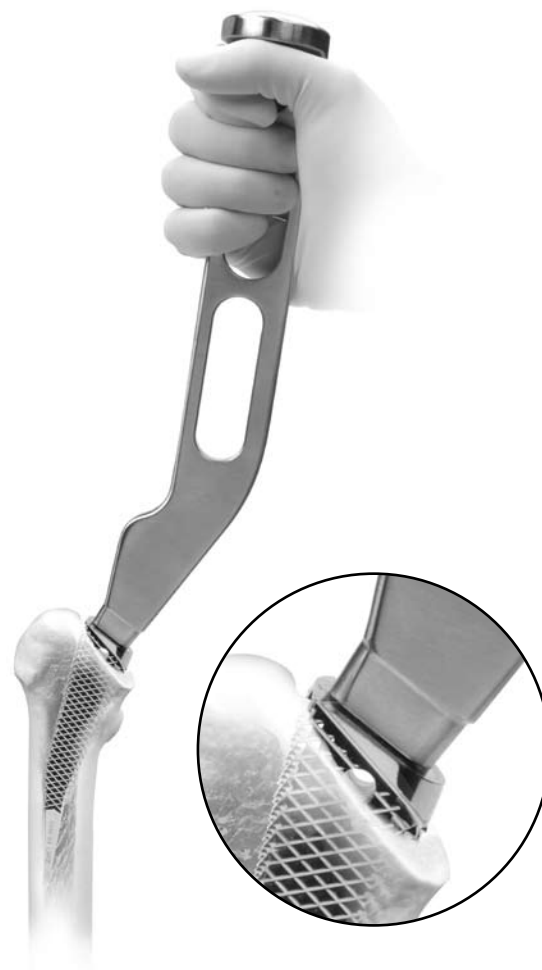


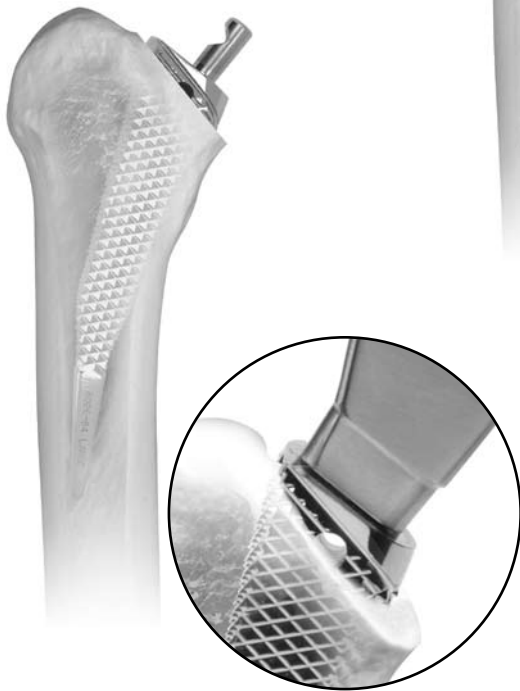Fig. 7

Perform progressive rasping until the rasp can no longer be advanced down the canal. **Note: If the rasp no longer advances with modest impaction force and if a solid sound of impaction is heard, STOP! Do not force the rasp any further down the canal (see scenarios 1 and 2).**

### Scenario 1

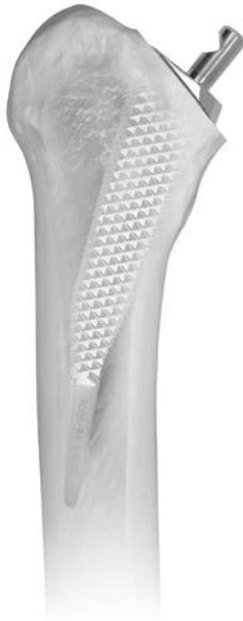If the top row of teeth of the final rasp is proud to the osteotomy line, the implant will also be proud.

In this case, a shorter neck length head may be required. The selected head will be based upon the trial reduction site.



### Scenario 2

A rasp that is flush with the osteotomy line will likely result in an implant that will be in a similar position. Again, the trial reduction will determine which neck length head to select.

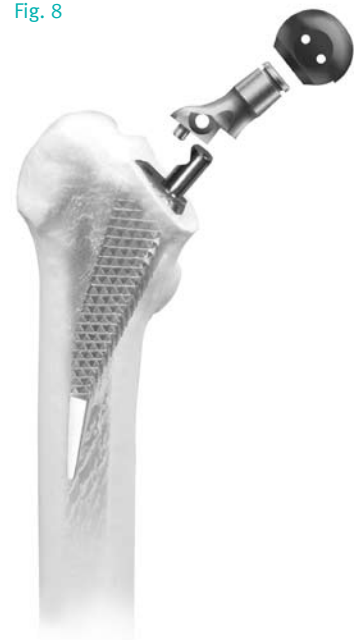

### Step 5 - Stability and Trial Reduction (Open Procedure)

With proper preparation, the proximal row of teeth on the rasp should be even with, or slightly proximal to the level of neck resection (Fig. 8). Rotate the handle and maneuver it in varus and valgus to assess stability of the rasp. Then remove the rasp handle and insert the provisional femoral neck and head (Fig. 8). The length dimensions are identical to those of other Zimmer hip systems. As with other designs, the usual resection, approximately a fingerbreadth above the lesser trochanter, is consistent with the standard length femoral neck modular component. There are two cone provisionals. One is labeled S/M and the other L/XL. See the table below to match the cone provisional with the corresponding rasp.

Cone Provisional		
Rasp Size	S/M	L/XL
	XS+	L
	S	L+
	S+	XL
	M	
	M+	

Fig. 8



### Step 6 - Component Insertion

The implant can be inserted with manual pressure to a depth requiring approximately 15mm further impaction (Fig. 9). Impact the device again so the dimple on the proximal portion is at, or just below, the level of neck resection (Fig. 10). This level is obtained if the rasp has been inserted to, or just past, the last row of teeth.

Fractures from excessive hoop stresses are rare if these two technical considerations are followed. Discontinue impaction of the femoral component if there is no progress down the canal with modest impaction force. If the implant remains proud, perform a trial reduction with the shorter neck modular implant.




Fig. 9

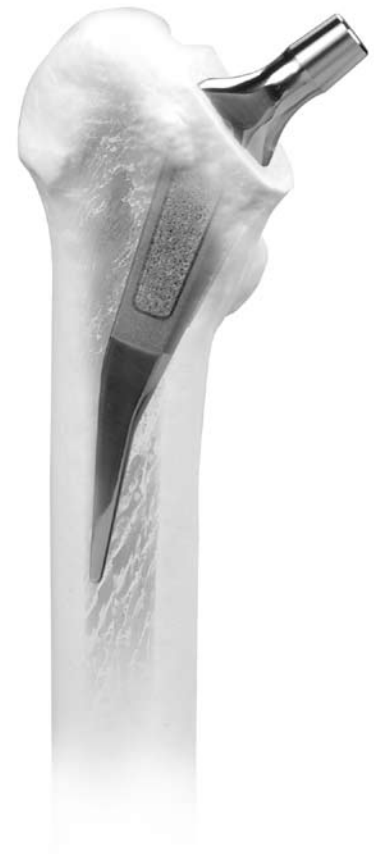

Fig. 10

### Anteversion

Femoral rasping is performed without consideration of the femoral anteversion since the rasp can follow only one path down the canal in the lateral plane. Therefore, the femoral anteversion of the implant is dictated by the anteversion of the proximal femur (Fig. 11). In those instances in which excessive anteversion exists, the neck is resected more distally. This lessens the deforming influence of the excessive anteversion.

### Attachment of the Femoral Head

When the stem is fully inserted, check to ensure that the 12/14 taper is clean and dry.

The 12/14 taper allows for use of standard Cobalt Chrome or Alumina Ceramic Head options. Place the selected femoral head on the taper and secure it firmly by twisting it and striking it once with the Head Impactor. Test the security of the head fixation by trying to remove it by hand.

*Note: Do not impact the femoral head onto the taper before driving in the prosthesis, as the femoral head may loosen during impaction of the stem.*

Reduce the hip, and assess leg length, range of motion, stability, and abductor tension for the final time.

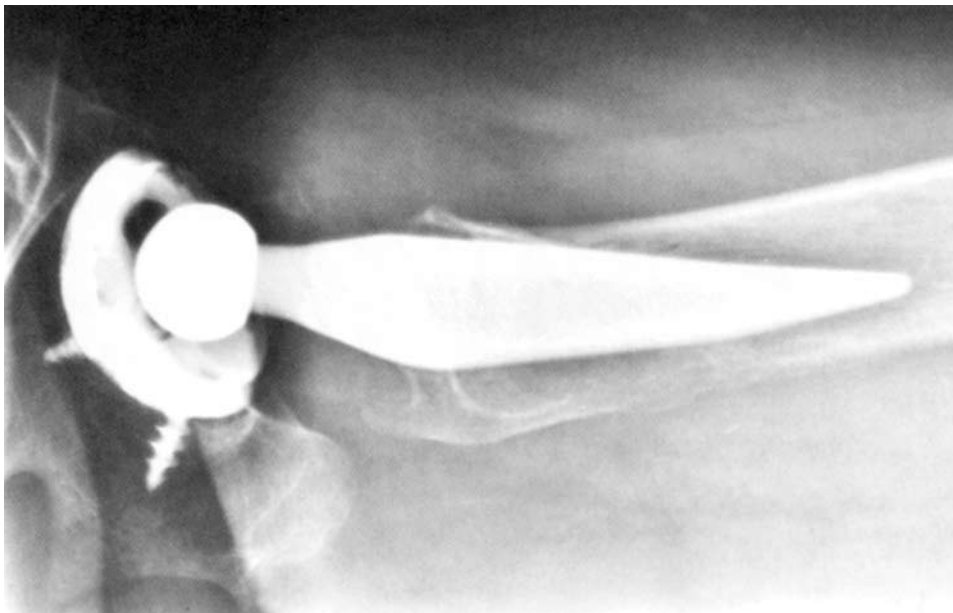


Fig. 11

## Technical Notes

### 1. Rasping the Femur

The most important surgeon decisions are which implant size and length of neck to use. Hence, proper rasping technique is the most critical step of the procedure. The depth of rasp insertion determines the proper size of the implant. The following considerations have proven helpful in assuring adequate fit without femoral fracture:

1. Start with the small rasp for all sized femurs. This allows proper orientation for subsequent size rasps. The ease of insertion provides an estimate of the ultimate size rasp and implant to be used.
2. If the rasp can be inserted to a depth of 5mm distal to the proximal row of teeth, use the next size rasp.
3. As greater resistance is encountered with the rasp, withdraw it about 10mm to 15mm to clear the teeth of debris. Then re-impact the rasp.
4. When the rasp shows no tendency to advance further, if the proximal row of teeth is at the level of neck resection, the standard length of neck is usually appropriate.
5. If the rasp shows no tendency to advance, but the proximal row of teeth is 2mm or more proximal to the neck resection, the shorter neck trials will be necessary.

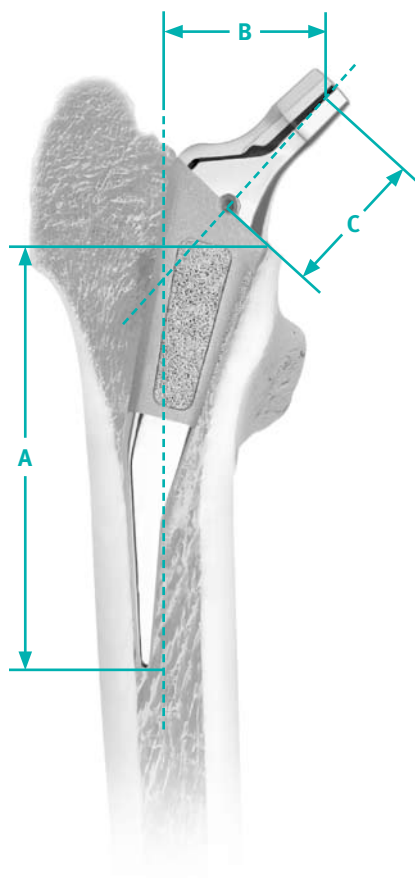
### 2. Implant Insertion

1. The implant matches the largest size rasp that was used. It can be inserted by manual pressure to within 15mm of the proper depth of insertion.
2. Use gentle but firm blows to drive the implant into place.
3. The sound of the impaction changes with the depth of insertion and fixation rigidity. As the implant approaches stability, it “bottoms out” and the sound of the impaction has a more “solid” sound.
4. The ideal depth of impaction is such that the implant dimple is at the level of the resected femoral neck.
5. Each successive size implant can be inserted to a depth of about 15mm proximal to the completely seated smaller size. From this position, the implant should be driven at least to a depth where the dimple is 5mm or 6mm proximal to the femoral neck cut. If the implant shows no tendency to advance further, do not force the implant further down the canal. Accept the position and use the shorter neck implant.
6. If the implant is rigid when the dimple is 2mm to 3mm distal to the line of resection, use the longer neck lengths. This is quite uncommon.

### Postoperative Rehabilitation

The postoperative rehabilitation program should be conservative. In the first month, increase the load by about 10 pounds per week. In the second month, the load progresses to about half-body weight. In the third month, full weight-bearing is allowed. The patient should use crutches for 8-10 weeks after surgery. A more aggressive return to weight-bearing depends on surgeon discretion based on the stability of the implant at the conclusion of implant impaction. Begin abduction strengthening exercises immediately after surgery and continue them for approximately three months.

Evaluate the patient after three months. If there is no evidence that the implant position has been altered and if the patient is having no symptoms, discontinue crutches and advise the patient on the use of a cane until this becomes no longer necessary (usually two to four weeks). Typically, patients are rechecked at one year and at regular intervals subsequent to this evaluation.



### MAYO Conservative Hip Prosthesis

Prod. No.	HA/TCP Prod. No.	Size	A Stem Length	B Offset when 12/14 Taper Head/Neck Component is:					C Neck Length
				-3.5	0	+3.5	+7.0	+10.5	
00-8026-011-00	65-8026-011-00	Small	81	35	38	40	43	45	30
00-8026-011-05	65-8026-011-05	Small +	85	36	39	41	44	46	30
00-8026-012-00	65-8026-012-00	Medium	89	37	40	42	45	47	31
00-8026-012-05	65-8026-012-05	Medium +	94	38	41	44	46	49	31
00-8026-013-00	65-8026-013-00	Large	98	40	43	45	48	50	33
00-8026-013-05	65-8026-013-05	Large +	102	41	44	46	49	52	33
00-8026-014-00	65-8026-014-00	X-Large	107	43	46	48	51	53	34



Please refer to package insert for complete product information, including contraindication, warnings, precautions, and adverse effects.

Contact your Zimmer Representative or visit us at [www.zimmer.com](http://www.zimmer.com)

